



PATIENT

Ella Morrissey

SPECIES

Canine

BREED

Maltese

SEX

FS

AGE

13 y

WEIGHT

6.4 kg

INTERPRETED BY

Keith Blass, DVM, MS,
DACVIM (Cardiology)

IMAGING PERFORMED BY

Dr. Brian Barnes

HOSPITAL NAME

Westview VH

REFERRING VET

Dr. Barnes

INVOICE

DATE

4/21/26

PRESENTING CLINICAL SIGNS

Recheck degenerative valve disease. PLN being treated with telmisartan and clopidogrel. Tracheal collapse treated with hydrocodone.

ECHOCARDIOGRAPHIC FINDINGS

2D, M-mode, and Doppler study. This exam is compared to the one performed 4/8/25.

Left atrial size is normal. The mitral valve leaflets are mildly thickened and exhibit systolic prolapse. There is Doppler evidence of mitral regurgitation present. Left ventricular dimensions are normal. Left ventricular systolic function is normal. The aorta and aortic valve are normal. Right atrial and right ventricular dimensions are normal. The tricuspid valve leaflets are mildly thickened, and there is Doppler evidence of tricuspid regurgitation present. TR velocity does not suggest the presence of pulmonary hypertension. The pulmonary artery and pulmonic valve appear normal, though trace pulmonic insufficiency is present. No shunting lesions are visualized. No pericardial or pleural effusion is seen.

ECG during echo: Sinus arrhythmia

LA - 24.8 mm (prev. 24.9 mm)

LVIDd - 22.5 mm (prev. 21.8 mm)

LVIDs - 12.4 mm (prev. 13.9 mm)

FS - 44.9% (prev. 36%)

RA - 16.8 mm (prev. 16.4 mm)

LVOT - 1.39 m/s (prev. 1.37 m/s)

RVOT - 1.14 m/s (prev. 1.03 m/s)

TR - 2.13 m/s (prev. 1.76 m/s)

ASSESSMENT/RECOMMENDATIONS

Degenerative mitral and tricuspid valve disease - stage B1

This examination demonstrates no progression of Ella's valvular diseases over the past year. As such, her risk for the development of clinical signs secondary to them still appears to be low.

No therapy is recommended at this stage of Ella's valvular diseases.

A recheck echocardiogram is recommended in 9 months to monitor for disease progression.



PATIENT

Ella Morrissey

SPECIES

Canine

BREED

Maltese

SEX

FS

AGE

13 y

WEIGHT

6.4 kg

INTERPRETED BY

Keith Blass, DVM, MS,
DACVIM (Cardiology)

IMAGING PERFORMED BY

Dr. Brian Barnes

HOSPITAL NAME

Westview VH

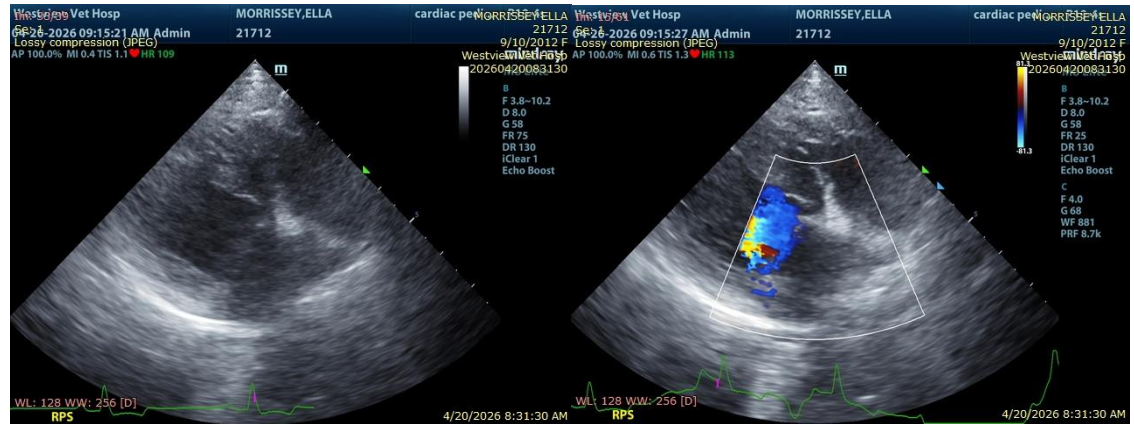
REFERRING VET

Dr. Barnes

INVOICE

DATE

4/21/26



The information and recommendations provided are based on the images presented by the referring veterinarian/sonographer. No evaluation can be communicated regarding pathology that was not visible in the image/video clips provided.

Thank you for this referral. If the clinical or image interpretation does not parallel your findings or if I can be of any further assistance please contact me.

Keith Blass, DVM, MS, DACVIM (Cardiology)

info@SonoPath.com